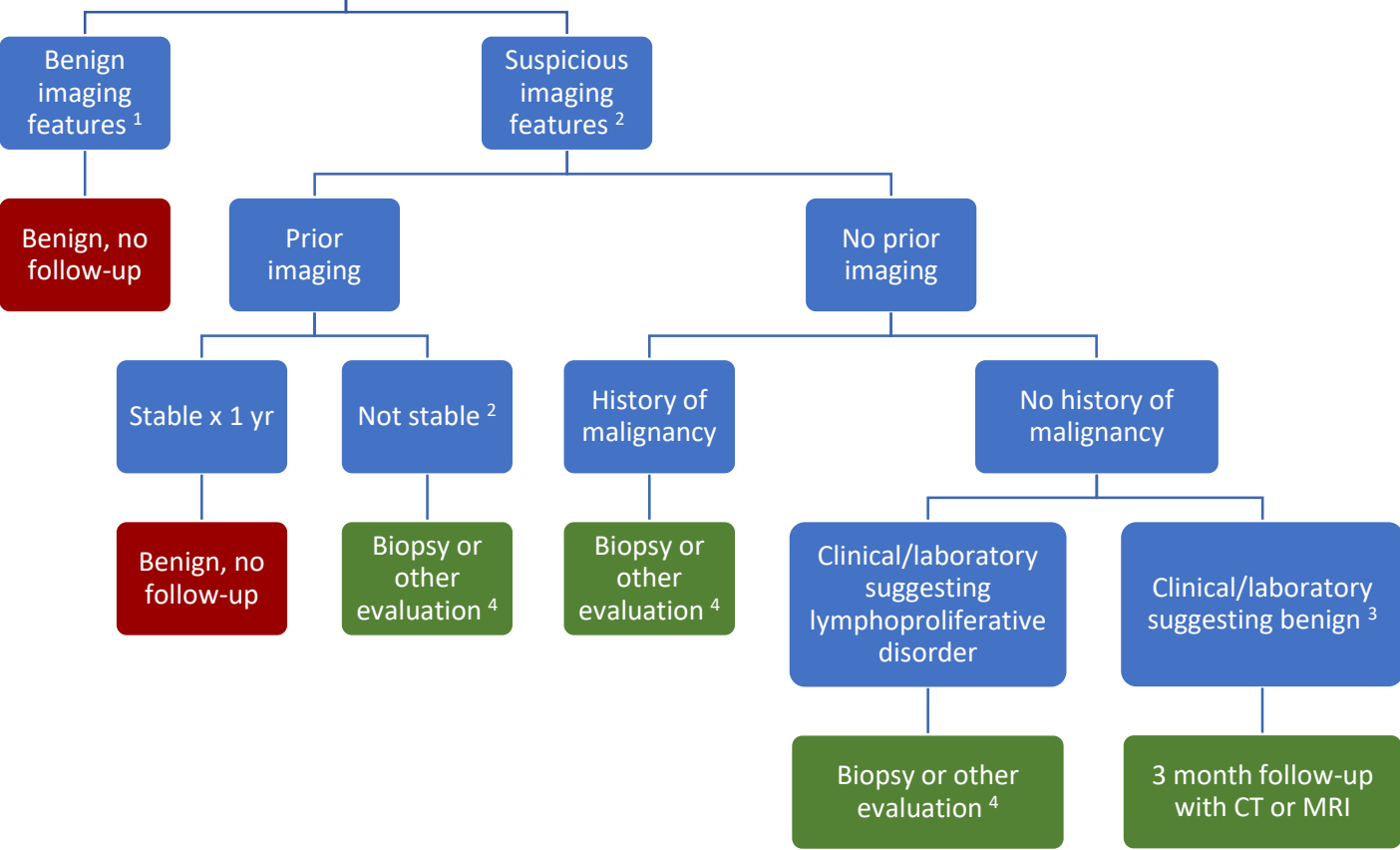


Incidental Lymph Node Findings on CT or MRI



¹ Benign features	Normal short-axis diameter (<1 cm in retroperitoneum), normal architecture (elongated, fatty hilum), normal enhancement, normal node number.
² Suspicious features	Enlarged short-axis diameter (≥1 cm in retroperitoneum), abnormal architecture (round, indistinct hilum), enhancement (necrosis/hypervascular), increased number (cluster of ≥3 lymph nodes in single nodal station or cluster of ≥2 lymph nodes in ≥2 regions).
³ Non-neoplastic disease	For example: Infection, inflammation, connective tissue disorders.
⁴ Other evaluation	PET/CT, nuclear scintigraphy (MIBG), endoscopic ultrasound.

Reference: *Heller MT, Harisinghani M, Neitlich JD, Yeghiayan P, Berland LL. Managing Incidental Findings on Abdominal and Pelvic CT and MRI, Part 3: White Paper of the ACR Incidental Findings Committee II on Splenic and Nodal Findings. J Am Coll Radiol 2013;10:833-839.*